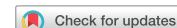


ARTICLE



The origins of the camper's chiasm asymmetry: a cadaveric study and clinical implications for flexor tendons surgery

Diego Faccio^a, Sara Montanari^b, Nicola Maschio^c, Franco Bassetto^d, Cesare Tiengo^e and Francesco Messana^a 

^aResident in Plastic and Reconstructive Surgery, University Hospital of Padua, Padua, Italy; ^bResident in Orthopedics, University Hospital of Verona, Verona, Italy; ^cOrthopedic Surgeon, Alto Vicentino Hospital, Vicenza, Italy; ^dOrdinary Professor and Head of the Department of Plastic and Reconstructive Surgery, University Hospital of Padua, Padua, Italy; ^eAssociate Professor of Plastic and Reconstructive Surgery, University Hospital of Padua, Padua, Italy

ABSTRACT

The Camper's chiasm (CC) originates from the decussation of tendon fibers of the flexor digitorum superficialis at the level of the proximal phalanx. Previous studies described several conformations of the CC, but none has studied the asymmetry pattern for each finger. We lack studies about the relationship between the vincula tendinum and the morphology of the CC. We aimed to study the precise pattern of asymmetry and the aforementioned relationship in a cadaveric study. We studied the fingers of 9 fresh frozen human hands (thumb excluded). We observed the distribution of the fibers and categorized each CC according to the Gonzalez classification. Finally, we recorded the inset point of the vincula longa superficiales (VLS) according to Schmidt. We found 7 symmetrical CCs, while the remaining 29 showed an asymmetrical pattern that matched with the site of insertion of the VLS. For the index and long fingers, we detected a dominance of the ulnar slip. For the ring and little finger, we found a higher radial dominance. The inset point of the VLS always coincided with the side of slip dominance, whereas in symmetrical CCs, the VLS was symmetrical as well. Since the vascular role of the vincula tendinum, we speculate that the asymmetry of the CC may be of vascular origin.

ARTICLE HISTORY

Received 15 March 2022
Revised 1 September 2022
Accepted 11 December 2022

KEYWORDS

Camper's chiasm; flexor tendons; flexor digitorum superficialis; tendon repair; tendon reconstruction; tendon transfer

Introduction

The flexor tendons of the hand are extremely organized structures composed mainly of collagen fibers and tenocytes [1]. Two flexor tendons, in close relationship with each other, pass without any obstacle through the very narrow digital canal [2].

In his '*Demonstrationum anatomico-pathologicarum liber primus continens brachii humani fabricam et morbo*', the anatomist Petrus Camper described the chiasm for the first time in 1760 [3]. The chiasm is the intersection between the two slips of the flexor digitorum superficialis (FDS) tendon after they surround the deep flexor located in the Zone 2 of Verdan and Michon, also known as *No man's land* [4,5].

In the passage under the A2 pulley, the FDS tendon splits into the radial and the ulnar slips. These rotate around the flexor digitorum profundus (FDP) tendon and unify dorsally to form the chiasm. Then, they separate again into two distinct insertions in the middle third of the middle phalanx [6]. The chiasm is paramount for the stability and dynamic function of the entire flexor apparatus. The complex morphology of the FDS tendon allows an independent flexion of the proximal interphalangeal joint, stabilizes the proximal interphalangeal (PIP) joint, and ensures a smooth sliding surface for the FDP tendon [7,8] (Figure 1).

The digital pulley system is a complex and well-described structure. Its deep and superficial anatomical landmarks are essential to plan and perform minimally invasive surgery. A thorough understanding of the relationship between the skin, the pulleys, and the flexor tendons guides the surgeon throughout surgery.

In addition, each flexor tendon generally has two sets of vascular supplies that come through the vincula brevia and vincula

longa tendinum. The vinculum brevis superficialis (VBS) arises from the membranous portion of the volar plate at the PIP joint, and it inserts onto the decussation. The vinculum brevis profundus (VBP) originates from the distal two-thirds of the middle phalanx. The vinculum longum superficialis (VLS) arises from the radial or ulnar side of the base of the proximal phalanx, and we usually find its insertion on one of the two slips of the FDS, just proximal to the decussation. The vinculum longum profundus (VLP) bridges between the FDP tendon and VBS through the decussation of the FDS tendon [9] (Figure 2).

Schmidt et al. in 1994 and Gonzalez et al. in 1998 published their studies on the asymmetries of the Camper's chiasm. They also classified the pattern of the fibers' decussation into nine (Schmidt) and ten (Gonzalez) subtypes [10,11]; however, these works did not examine a possible vascular explanation for the asymmetries, nor observed any precise pattern of asymmetry subdivided for each finger.

Our cadaveric study aimed to find the relationship between the position of the vincula longa superficiales of each FDS and the pattern of asymmetry of the chiasm. In addition, we looked for any relevant clinical application of the chiasm's asymmetry in flexor tendon surgery.

Materials and methods

We conducted our study during the VIII Course of Dissection and Surgical Anatomy, held by the Italian Society of Hand Surgery (SICM) at the ICLO center of Arezzo, Italy in 2018.

We studied the relationship between the vincula longa tendinum and FDS, along with the decussation pattern of the Camper's chiasm in 36 fingers of 9 fresh frozen human hands (5 right hands and 4 left hands; 6 belonged to males and 3 to female subjects). Thumbs were excluded from the study.

We exposed the flexor apparatus through a volar Brunner type incision. The pulleys were then vented on their long axis exposing the inner part of the digital canal from the A1 pulley to the distal insertion of the FDP tendon.

The FDP was dissected to the palm and overturned while maintaining the distal insertion. This way, we could observe the anatomy of Camper's chiasm, with particular attention to the arrangement of the tendon fibers with their vascularization through the vincula.

Under 3.5x prismatic magnification loupes (Univet® SRL, Rezzato (BS) – Italy) we observed the decussation pattern of each chiasm and registered it for each finger on a table using the Gonzalez classification [11] (Figure 3). The greater contribution of the ulnar or radial slip was recorded as well. All observations were assessed with the finger fully extended. We also registered the insertion of the vincula onto the FDS and the side of origin.

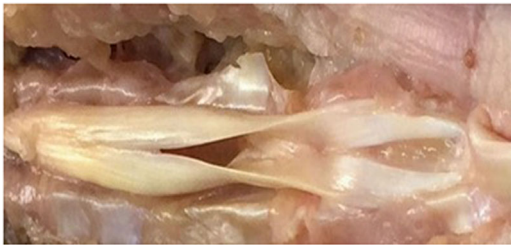


Figure 1. The two slips of FDS (Flexor Digitorum Superficialis) and a symmetrical Camper's chiasm of a left ring finger.

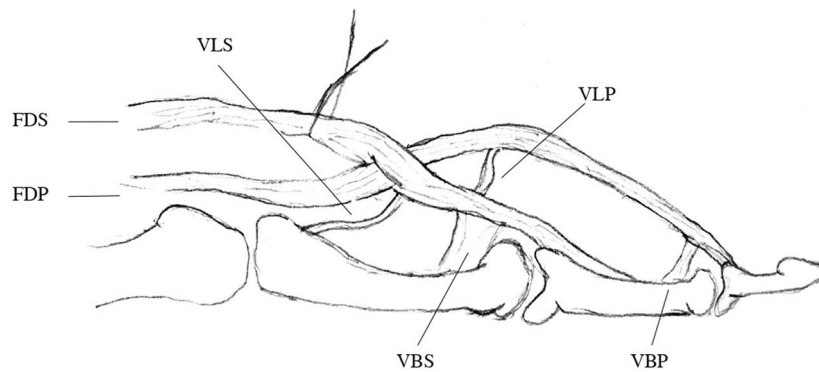


Figure 2. Vincular system of finger. FDS: Flexor Digitorum Superficialis, FDP: Flexor Digitorum Profundus, VLS: Vinculum Longum Superficialis, VLP: Vinculum Longum Profundus, VBS: Vinculum Brevis Superficialis, VBP: Vinculum Brevis Profundus.

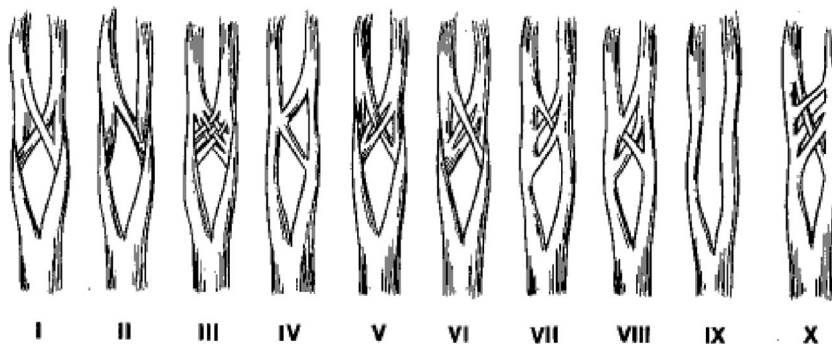


Figure 3. The Gonzalez classification scheme as proposed on the original article from 1998.

Results

Observing the structure of the chiasm, we found several asymmetries of the two slips of the FDS (Table 1). We also found a relevant correspondence between the insertions of the vincula longa superficiales and the dominant slip of a given chiasm.

In all nine hands, the ulnar slip of the index and long fingers immediately proximal to the chiasm was macroscopically thicker than the radial one, and a part of the ulnar fibers crossed univocally towards the radial side (Type 2 according to Gonzalez [11]). These were the only fibers forming the Camper's chiasm. We did not observe any fibers from the radial slip that crossed to the ulnar side. Distally to the chiasm, the fibers that had crossed to the radial side became part of the radial slip and constitute a reinforcement of its insertion into the middle third of the middle phalanx (Figures 4 and 5).

In the ring and little fingers, the Camper's chiasm was more variable. In six ring fingers, the radial slip immediately proximal to the chiasm was macroscopically thicker than the ulnar one, and part of the radial slip crossed towards the ulnar side (Type 6-7-8-10 of Gonzalez, [11]). In three ring fingers, the Camper's chiasm was formed by the bidirectional decussation of the two slips (Type 1-3 of Gonzalez, [11]). In the same way, in five little fingers, only a radio-ulnar decussation formed the Camper's chiasm (Type

Table 1. Distribution of the chiasms' conformation for each finger according to the Gonzalez classification.

Type	I	II	III	IV	V	VI	VII	VIII	IX	X
<i>Index</i>	0	9	0	0	0	0	0	0	0	0
<i>Long</i>	0	9	0	0	0	0	0	0	0	0
<i>Ring</i>	3	0	0	0	0	2	2	1	0	1
<i>Little</i>	3	5	1	0	0	0	0	0	0	0
Tot.	6	23	1	0	0	2	2	1	0	1

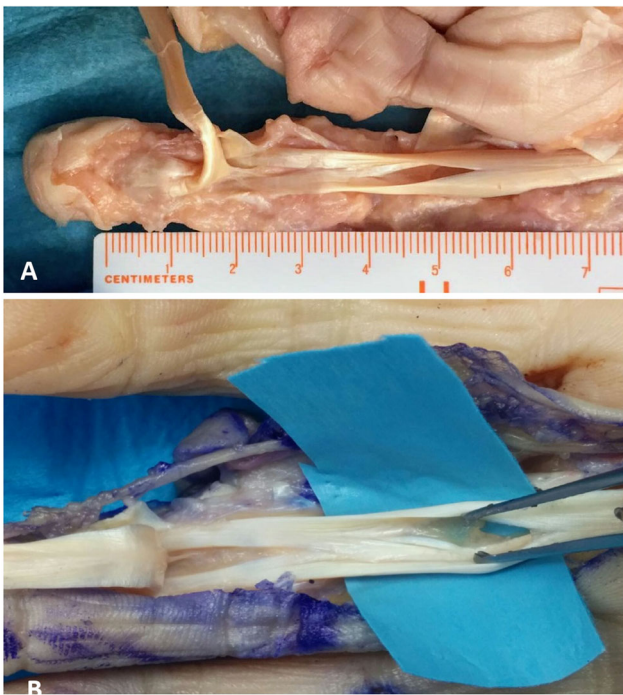


Figure 4. Two examples of asymmetric representation of the FDS slips of the II left finger (a) and the III right finger (b) with unidirectional ulno-radial decussation at the level of the Camper’s chiasm in a cadaveric model.

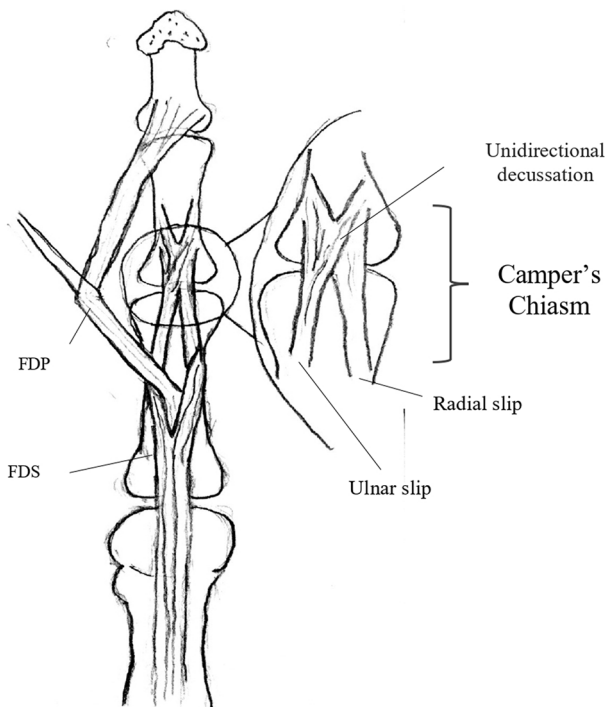


Figure 5. Graphic representation of the unidirectional ulno-radial decussation at the level of the Camper’s chiasm.

Table 2. Distribution of the inset point of the Vincula Longa Superficiales onto the chiasm according to the Schmidt classification.

Type	Proximal	Central	Distal	Ulnar	Radial
Index	0	0	0	9	0
Long	0	0	0	9	0
Ring	0	1	2	0	6
Little	2	1	1	0	5
Tot.	2	2	3	18	11

2 according to Gonzalez, [11]). In the remaining four little fingers, the chiasm showed a bidirectional decussation of the two slips (Type 1-3 of Gonzalez, [11]).

We also observed the proximal origin and the insertion of the vincula longa onto the FDS tendons and classified it according to Schmidt et al. [10] (Table 2 and Figure 6). By gently retracting the flexors with a tendon hook, we identified the vincula longa and followed them proximally until they emerged from the transverse communicating branch that entered the digital canal at the base of the proximal phalanx. The vinculum can be single and have a unilateral ulnar or radial origin, or there can be two vincula with symmetrical origins on both sides.

When only the decussation of the ulnar fibers (index and long fingers) or the radial fibers (mainly ring and little fingers) formed the chiasm (Type 2 chiasms), the origin and inset of the vinculum lay on the ulnar or radial side of the digital fibrous canal, respectively (Figure 7).

In cases of a symmetrical bidirectional cross (Type 1-3 chiasms), the vincula had a proximal, central, or distal inset point, whereas in the case of an asymmetrical decussation (Type 6-7-8-10) we found a radial or ulnar inset of the vincula. The morphology of the Camper’s chiasm matched with the inset of the vincula, and therefore with the tendons’ vascular supply.

Discussion

Our anatomical study describes the asymmetry of the Camper’s chiasm fibers and the correspondence with the asymmetrical blood supply provided by the vincula. We believe that the significance of these findings relies on a new hypothesis observed here for the first time and on the possible clinical applications of this anatomical asymmetry.

Schmidt et al. [10] observed 228 chiasma tendina in 240 fingers and classified them into nine common types and miscellaneous variations. They also described five different points of inset of the vincula longa onto the chiasma tendinum. Four years later, Gonzalez et al. [11] conducted a similar study and proposed their new classification, which included a new type (type 10) and rearranged some of the Schmidt’s subtypes. In all of our index and long fingers, we observed the same type of conformation (type 3 according to Schmidt and type 2 according to Gonzales) in which a single bundle of fibers crossed from the ulnar to the radial side.

A recent study published by Dinç et al. [12] studied the morphology of the chiasm and its anatomical relations with the pulley system. Nonetheless, none of the works cited above studied the precise asymmetry pattern divided by each finger. Our paper reports for the first time the exact pattern of asymmetry (ulnar or radial prevalence for each finger) and the relationship between the position of the vincula longa and the dominance of one slip over the contralateral.

We hypothesize that the asymmetry can be explained by an asymmetrical blood supply of the two slips of the FDS at the Camper’s chiasm. This is particularly evident on the index and long fingers, in which the vascularization of the vincula reaches only the ulnar slip. Here we found an exclusive decussation of the fibers of the ulnar slip to the radial one. The decussating portion contains the vascular axis that conveys the blood flow towards the slip of the opposite side.

The knowledge of the vascular supply’s distribution could potentially contribute to improving tendon repair and reconstruction techniques, although the true clinical role of our hypothesis is still unknown. A rich blood supply is fundamental in the processes of wound healing: it conveys the nutrients that allow the

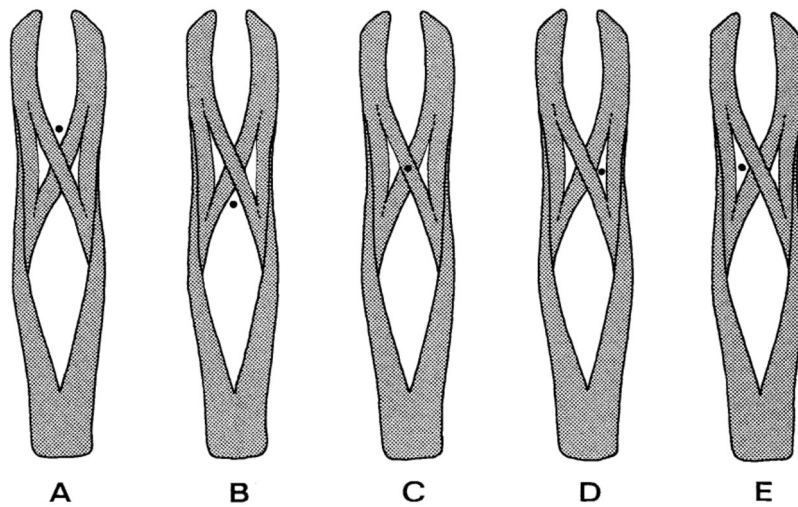


Figure 6. The relationship of the VL and FDS as proposed by Schmidt in his original article on 1994. The dots show the position of the Vincula. A) Distal; B) Proximal; C) Central; D) Ulnar; E) Radial.

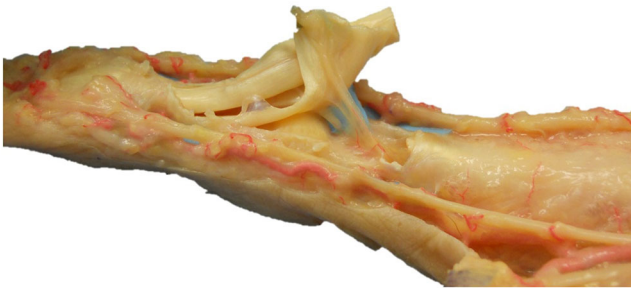


Figure 7. Ink latex injected right index finger. The origin of Vinculum Longum Superficialis from the ulnar side of the digital fibrous canal and its inset point onto the ulnar side of the chiasm.

tenocytes to deposit regular collagen fibers, which will restore the continuity of the tendon with minimal fibrosis [13]. For example, in the case of traumatic lesions of both slips of the FDS, the repair of the most vascularized slip translates into restoring the tendon's portion that has a better resistance and greater chances of healing.

In the case of major lesions that involve both flexor tendons in zone 2 of Verdan, the ideal goal would be the full restoration of both tendons; however, this generally causes an excessive bulkiness at the suture site, which impairs the tendon sliding through the digital canal [14]. If that is the case, the exclusive tenorrhaphy of the FDP or the FDP associated with only one slip of the FDS ensures the compromise between suture strength and tendon gliding in the post-operative period [15–18].

In addition, the precise knowledge of the anatomic landmarks of the pulley system thoroughly described by other Authors is paramount for hand surgeons. This way, we can limit the extension of the skin incisions, preserve the integrity of the pulley system as much as possible, and decide the most suitable reconstructive option concerning the zone of injury [12,19].

This study has some limitations, such as the relatively small number of fingers examined, the absence of histologic measurements of the slips' width, and the lack of a clinical trial that tests the long-term outcomes when using the ulnar or the radial slip for tendon reconstruction or palliative tendon transfers. We are looking forward to new studies on this subject since the incidence of tendon and nerve lesions is highly relevant.

In conclusion, the Camper's chiasm is a complex structure that often encompasses an asymmetrical distribution of its tendon

fibers. For the first time, we observed a precise correlation between the insertion of the vincula longa and the dominance of one slip of the FDS over the other. We especially observed this pattern in the index and long fingers, and we believe that this finding could explain the development of this asymmetry.

Acknowledgements

The authors gratefully thank Daniel McAndrew-Greiner for the English editing and language support.

Disclosure statement

No potential conflict of interest was reported by the author(s).

Funding

This research received no specific grant from any funding agency in the public, commercial, or not-for-profit sectors.

ORCID

Francesco Messina  <http://orcid.org/0000-0002-4613-6697>

References

- [1] Verzar F, Huber K. Die struktur der Sehnen-Faser [structure of tendon fibers]. *Acta Anat.* 1958;33(3):215–229.
- [2] Ijpmma FFA, van de Graaf RC, van Gulik TM. Petrus camper's work on the anatomy and pathology of the arm and hand in the 18th century. *J Hand Surg Am.* 2010;35(8):1382–1387.
- [3] Camper P. *Demonstrationum anatomico-pathologicarum liber primus continens brachii humani fabricam et morbos.* Amsterdam: Joann Schreuder et Petrum Mortier; 1760. p. 1–22.
- [4] Nicholson LT, Hill JR, McKnight B, et al. Redefining zone II: anatomy of the flexor digitorum superficialis insertion. *Hand.* 2019;14(3):377–380.
- [5] Verdan C, Michon J. [The treatment of injuries of the flexor tendons of the fingers. *Rev Chir Orthop Reparatrice Appar Mot.* May-Jun. 1961;47:285–425.

- [6] Shrewsbury MM, Tucker AB. A study of the flexor digitorum superficialis tendon in flexion and extension at the proximal interphalangeal joint. *Bull Hosp Joint Dis.* 1975;36(1):40–47.
- [7] Tang JB, Xu Y, Chen F. Impact of flexor digitorum superficialis on gliding function of the flexor digitorum profundus According to regions in zone II. *J Hand Surg Am.* 2003;28(5):838–844.
- [8] Zafonte B, Rendulic D, Szabo RM. Flexor pulley system: anatomy, injury, and management. *J Hand Surg Am.* 2014;39(12):2525–2532; quiz 2533.
- [9] Ochiai N, Matsui T, Miyaji N, et al. Vascular anatomy of flexor tendons. I. Vincular system and blood supply of the profundus tendon in the digital sheath. *J Hand Surg Am.* Jul. 1979;4(4):321–330.
- [10] Schmidt HM, Zhang SX, Zieseniss K. Clinical anatomy of the chiasma tendinum (camper) in the fingers. *Clin Anat.* 1994;7(2):65–71.
- [11] Gonzalez MH, Nikoleit J, Weinzeig N. The chiasma of the flexor digitorum superficialis tendon. 1998.
- [12] Dinç U, Şengezer E, Beger O, et al. Morphological features of the chiasma tendinum and its relation with surface landmarks and pulleys: a cadaveric study. *Surg Radiol Anat.* 2021;43(10):1623–1633.
- [13] Leffert RD, Weiss C, Athanasoulis CA. The vincula; with particular reference to their vessels and nerves. *J Bone Joint Surg Am.* 1974;56(6):1191–1198.
- [14] Pike JM, Gelberman RH. Zone II combined flexor digitorum superficialis and flexor digitorum profundus repair distal to the A2 pulley. *J Hand Surg Am.* 2010;35(9):1523–1527.
- [15] Jordan RW, Lotfi N, Shyamalan G. Simultaneous closed rupture of flexor digitorum superficialis and flexor digitorum profundus tendons in the Middle finger: a case report. *Case Reports Plast Surg Hand Surg.* 2015;2(1):1–3.
- [16] Geary MB, English C, Yaseen Z, et al. Flexor digitorum superficialis repair outside the A2 pulley after zone II laceration: gliding and bowstringing. *J Hand Surg Am.* 2015;40(4):653–659.
- [17] Tang JB, Xie RG, Cao Y, et al. A2 pulley incision or one slip of the superficialis improves flexor tendon repairs. *Clin Orthop Relat Res.* 2007;456:121–127.
- [18] Zhao C, Amadio PC, Zobitz ME, et al. Resection of the flexor digitorum superficialis reduces gliding resistance after zone II flexor digitorum profundus repair In vitro. *J Hand Surg Am.* 2002;27(2):316–321.
- [19] Gordon JA, Stone L, Gordon L. Surface markers for locating the pulleys and flexor tendon anatomy in the palm and fingers with reference to minimally invasive incisions. *J Hand Surg Am.* 2012;37(5):913–918.